

Use of an oral appliance in a marked retrognathic and severe OSA patient. Three years follow-up: clinical report

Uso de um aparelho intraoral no tratamento da AOS grave em um paciente com severa alteração craniofacial. Três anos de acompanhamento: relato de caso

Lílian Chrystiane Giannasi¹, Renata Costa de Almeida², Raquel Pastrello Hirata¹, Luis Vicente Franco Oliveira¹

ABSTRACT

The aim of this study was to show the efficacy of mandibular repositioning appliance (MRA) to treat severe obstructive sleep apnea (OSA) on a marked retrognathic patient that refused continuous positive airway pressure (CPAP) therapy. The apnea/hypopnea index (AHI) reduced from 38.5 to 12.0, despite marked retrognathia represented for the variable $\text{pog/N-perp} = -15.0$ mm. After six months and after three years of MRA usage, another polysomnogram (PSG) was carried out. The results showed an AHI=12.0 and 13.0, respectively, besides improvements in other physiologic variables. We concluded that MRA was effective in the treatment of severe OSA with a marked retrognathia. Sleep physicians should consider this therapy option when patients refuse CPAP and surgery approaches.

Keywords: Sleep apnea, obstructive/therapy; Orthodontic appliance design; Orthodontic appliances, functional; Mandibular advancement/instrumentation; Retrognathism

RESUMO

O objetivo deste estudo foi demonstrar a eficácia do uso do aparelho reposicionador mandibular (ARM) para o tratamento da apnéia obstrutiva do sono (AOS) grave em um paciente com severa alteração craniofacial e que recusou a terapia com pressão positiva contínua nas vias aéreas (CPAP). O índice de apnéia e hipopnéia (IAH) reduziu de 38,5 para 12,0, apesar de a alteração craniofacial representada para a variável $\text{pog/N-Perp} = 15,0$ mm. O exame de polissonografia (PSG) foi realizado com o aparelho *in situ* após seis meses de uso e após três anos. Os resultados mostraram IAH=12,0 e 13,0, respectivamente, além de melhoras em outras variáveis fisiológicas. Concluímos que o ARM foi efetivo no tratamento da AOS grave acompanhada de uma severa alteração craniofacial. Médicos do sono devem considerar essa opção terapêutica quando pacientes portadores de SAOS grave recusarem o uso de CPAP e técnicas cirúrgicas.

Descritores: Apnéia do sono tipo obstrutiva/terapia; Desenho de aparelho ortodôntico; Aparelhos ortodônticos funcionais; Avanço mandibular/instrumentação; Retrognatismo

INTRODUCTION

According to the recent practice guidelines about the treatment of obstructive sleep apnea (OSA) with an mandibular repositioning appliance (MRA), the continuous positive airway pressure (CPAP) is considered to be a gold standard treatment for moderate and severe OSA, and it is indicated whenever possible before considering oral appliance⁽¹⁾. Because OSA is a multifactor disease, its treatment demands a multiprofessional approach. Generally, for the moderate and severe OSA patients, the physicians consider the advantages of CPAP therapy, upper airway surgery, or a combination of both treatments and, in specific cases, a maxillo-mandibular advancement surgery is suggested. Nevertheless, most patients decline surgery options and refuse or discontinue the CPAP therapy even knowing that this one allows the best results for this pathology. In the daily clinic, even severe OSA individuals who also show cranioskeletal abnormalities, such as marked maxillary and/or mandible retraction, microgenia, maxillary atresia, and marked upper airway constriction, generally prefer using OA instead of orthognathic surgery. Among the best-studied alternative treatments for OSA there is the MRA, designed to hold the mandible forward during sleep, increasing upper airway dimension and preventing the narrowing/collapse of the pharynx^(2,3). Actually, there are several studies proving the efficacy and the safety of OA therapy^(3,4). Follow-up studies have identified some drawbacks of these appliances, such as excessive salivation, occlusive changes, and temporomandibular joint or dental pain, though these last mentioned effects appear to be rare and tolerated by the majority of the patients in cases series^(5,6). There is little literature focusing the efficacy of MRA treatment in severe OSA patients and also in severe

Study carried out at Sleep Laboratory of Universidade Nove de Julho – Uninove, São Paulo (SP), Brazil.

¹ Sleep Laboratory, Rehabilitation Sciences Master's Program, Universidade Nove de Julho – Uninove, São Paulo (SP), Brazil.

² Odontological Radiologist, Focus Dental Radiological Clinic, São José dos Campos (SP), Brazil.

Conflict of interest: the authors attest that there is no financial or other relationship that might lead to conflict of interest.

Corresponding author: Lílian Chrystiane Giannasi – Rua Franz de Castro Holzwarth, 103, sala 116 – Centro – CEP 12300-000 – Jacareí (SP), Brazil –Phone/Fax: (12) 3951-0800 – E-mail: odontogiannasi@uol.com.br

Received: March 3, 2009; Accepted: August 01, 2010

OSA patients with severe craniofacial alterations^(7,8). The aim of this case report was to share the results obtained with an MRA used in the treatment of severe OSA, over three years follow-up, in a patient with a severe retrognathia and micrognathia and refused CPAP usage.

CASE REPORT

A 32-year-old man with a body mass index (BMI) of 25.85 kg/m² and neck size of 42.0 cm was referred to us from a private sleep Medicine clinic to evaluate the possibility about the treatment of a severe OSA with a MRA. He underwent two polysomnograms (PSG), one basal PSG and one continuous positive airway pressure (CPAP) titration PSG. As indicated in Table 1, the apnea/hypopnea index (AHI) was 38.5, the minimum oxygen saturation (SaO₂ nadir) was 67.0%, the arousals index was 35.0/h and sleep efficiency (SE) was 94.7%. At the first appointment in the dentist office, he complained of snoring, nocturnal breathing arrests, tiredness upon awakening, and difficulty in concentrating. The score for Epworth Somnolence Scale (ESS) was 9.0 and, curiously, he related no excessive sleepiness. He related a vasomotor rhinitis, and from time to time he had to use a specific medication. When asked about CPAP treatment he said that during the sleep night titration he had difficulties to adapting to CPAP (11 cmH₂O) and refused to use it as a life therapy, since the AHI and arousals did not reduced, according to his expectation (Table 1). After this, he rented a CPAP for a month, to try once again this therapy, and related difficulties in adapting, probably due to his frequent nasal obstruction. Finally, he asked his sleep doctor for another treatment alternative, which was an oral appliance. The oral and facial evaluation revealed an ogival palate, a transversal atresic maxillary, the absence of the tonsils, an open mouth on rest, dental malocclusion class II, open bite, narrow face with vertical growth predominance, jaw on lower position, retrognathia and micrognathia (Figure 1). Patient's upper and lower arches presented all dental elements and temporomandibular joint (TMJ) palpation, and auscultation revealed no signs of dysfunction. A lateral cephalometric radiograph and upper and lower cast models were requested to evaluate the upper airway dimensions and dentoskeletal pattern. Cephalogram findings showed a marked maxillomandibular deficiency and a marked anteroposterior reduction of upper airways, severe retrognathia and the craniovertebral angulation was reduced (Table 2). Considering the degree of craniomaxillofacial abnormalities, the presence of severe OSA and the limited results with CPAP, a simultaneous maxillary and mandibular advancement (MMA) was suggested. It was explained that MMA is a surgery that has been shown

to be a highly effective treatment for apneic individuals with a maxillomandibular deficiency⁽⁹⁾, and after MMA an enlargement of upper airways occurs, and the collapsibility of the airway is decreased due to increased tension of the velopharyngeal and suprahyoid musculatures⁽¹⁰⁾. Despite all information given to the patient, he declined MMA option and preferred trying MRA as treatment for OSA before an invasive approach. The appliance chosen was the adjustable PM Positioner™, fabricated in two parts, joined together by two expanders on each side, which allow for titration according to each individual need. A constructive wax bite was approximately 60.0% of maximum protrusion, which was sent along with the cast models to the specialized laboratory for the OA manufacture. The increase in the vertical dimension did not exceed 7.0 mm, providing good appliance adaptation and effectiveness allied with comfort. The placement of the MRA proceeded (Figure 2) with advice given about the care and hygiene of the appliance. Similarly, the information about the follow-up visit twice a year and the need of a PSG once each two years was given. The initial titration was 1 mm and the subsequent titrations, 0.50 mm, were performed weekly to prevent TMJ symptoms. The total advancement reached about 9.0 mm and took about 2 months to complete. Side-effect related by the patient was only a dry mouth sensation lasted for the two first months. After six months and three years, a PSG was carried out to evaluate the efficacy of MRA over time.

Table 1: Polysomnogram findings from prior treatment to three year follow-up

PSG variables	Basal PSG	CPAP PSG	PSG after 6 months	PSG after 3 years
AHI	38.5	25.0	12.0	13.0
SaO ₂ min (%)	64.0	79.0	80.0	81.0
Arousal index	34.0	21.0	2.2	4.0
REM (%)	23.0	24.0	21.2	20.0
Sleep efficiency (%)	94.7	90.5	95.0	94.0

PSG: polysomnogram; CPAP: continuous positive airway pressure; AHI: apnea/hypopnea index; REM: rapid eye movement; SaO₂: minimum oxygen saturation.

Table 2: Cephalometric findings

Cephalometric values	Patient value	Normal value
SNB	74.0°	80.0°
ANB	5.5°	2.0°
PAS	8.8 mm	15.5 mm
CVA	86.0°	101.0 mm
Pog/N-Perp	-15.0 mm	0-1.0 mm

SNB: relationship of the mandible to the cranial base; ANB: relationship between upper and lower jaws; PAS: posterior airway space; CVA: angle between cranial and cervical spine; Pog/N-Perp: Pogonion to nasion perpendicular.

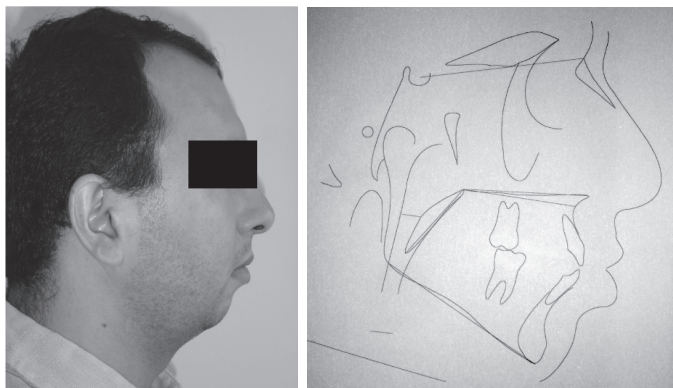


Figure 1: Patient facial pattern – severe retrognathia

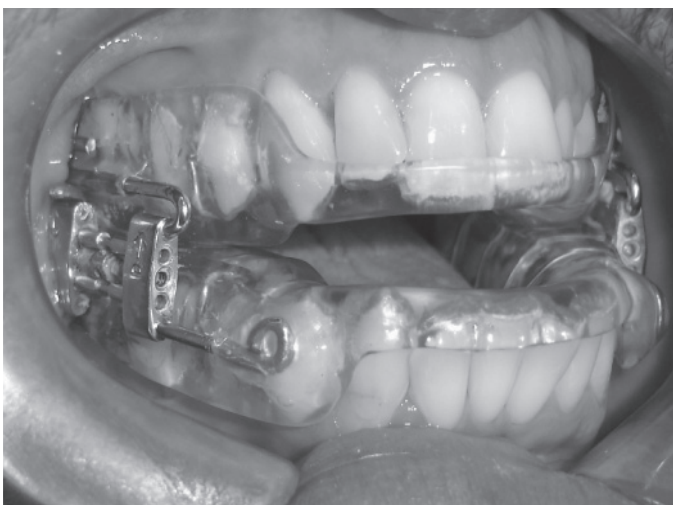

Figure 2: Lateral view of mandibular repositioning appliance (MRA) *in situ*

RESULTS

A comparison of the initial PSG and the PSG taken with the MRA *in situ* after six months (Table 1) revealed that snoring had significantly reduced, according to his spouse report, and the AIH has reduced from 38.5 to 12.0, the SaO₂ nadir rose from 67.0% to 80.0%, the arousals index decreased from 34.0 to 2.2, and there were improvement in other physiologic variables (Table 1). The results after three years of OA usage showed that MRA was still effective, with an AHI=13.0, and his wife stated that snoring was still reduced, but not totally eliminated. The patient related that subjective symptoms have improved, such as snoring, nocturnal breathing arrests, tiredness upon awakening, and difficulty in concentrating. ESS values remained the same, since the patient did not complain of excessive sleepiness before treatment.

DISCUSSION

The use of an MRA to treat a severe OSA with an AHI over 38.0 was efficient. Even the patient skeletal pattern presented unfavorable measures. It must be noted that, in

this case, the low BMI could have been an important factor to achieve the significant decrease of AHI⁽¹¹⁾. Another factor that must have contributed to this result was the presence of a marked retrognathia, with an angle between mandible and cranial base (SNB=74°), an angle between upper and lower jaw (ANB=5.8°)⁽¹²⁾ and the relationship of mandible to cranial base Pog/N-Perp= -15.0 mm⁽¹³⁾. A cephalometric study comparing 30 OSA patients to 30 normal ones showed that OA was more effective when SNB angle and posterior airway space (PAS) presented narrow values⁽¹⁴⁾. In our study, patient's PAS was 8 mm (Table 2) before treatment, which also converge to Otsuka et al.⁽¹⁵⁾ study, in which they stated that smaller dimensions of PAS are predictive success factor in responder patients, otherwise, the small values of SNB were not significant factor in the responder group, which was composed of mixed OSA severity. In a previous study⁽⁷⁾, the authors showed a favorable result using MRA to treat a severe OSA in two patients with craniofacial alterations. In our work, OA usage reduced the AHI from 38.5 to 12.0 events per hour after 6 months, and to 13.0 after 3 years. Barthlen et al.⁽¹⁶⁾ compared the efficacy of three types of oral device to treat severe patients and found that mandibular positioning appliance, as used in our study, was most effective to treat OSA in a group with severe patients only. In a recent study, a severe OSA was successfully treated with an OA⁽¹⁷⁾. We can find in the literature several articles showing the use of OA to treat OSA in a group that also have severe OSA patients^(2,3,14,15), but there are little articles using a group of severe OSA only^(7,16,17). Despite CPAP can reach better results, studies have shown that patients prefer MRA treatment⁽¹⁸⁾. The American Academy of Sleep Medicine (AASM)⁽¹⁾ states that MRA therapy should be used as first option on snoring and mild SAOS patients. Our patient's characteristics are not uncommon amongst successful OA therapy, and literature shows that most OSA patients are Cl II malocclusion⁽⁹⁾, but to our knowledge, there are no studies showing an OA treatment efficacy with three year follow-up in a severe OSA patient, independently of cephalometric characteristics. This result can bring more confidence to dentists to treat severe patients who cannot accept or adapt to CPAP treatment. We believe that other physiologic variables might be evaluated in further studies (e.g. blood pressure). Our study objectively showed that it is important to understand that, in specific cases, it is better to carry out a MRA treatment than leave the patient remains without any SAOS treatment.

CONCLUSION

The results after six months and three years of MRA use showed that the device was efficient to treat severe OSA;

its efficacy remained at an optimum level after three years, despite the craniofacial status presenting unfavorable values. Further studies focusing the evaluation of blood pressure in these cases are necessary, since the OA may be used for a long time to treat OSA.

ACKNOWLEDGMENT

We thank Fundação de Amparo à Pesquisa (Fapesp, acronym in Portuguese) and Conselho Nacional de Desenvolvimento Científico e Tecnológico (CNPq, acronym in Portuguese) for supporting this research.

REFERENCES

1. Kushida CA, Morgenthaler TI, Littner MR, Alessi CA, Bailey D, Coleman J Jr, Friedman L, Hirshkowitz M, Kapen S, Kramer M, Lee-Chiong T, Owens J, Pancer JP; American Academy of Sleep. Practice parameters for the treatment of snoring and Obstructive Sleep Apnea with oral appliances: an update for 2005. *Sleep*. 2006;29(2):240-3.
2. Tsuiki S, Hiyama S, Ono T, Imamura N, Ishiwata Y, Kuroda T, et al. Effects of a titratable oral appliance on supine airway size in awake non-apneic individuals. *Sleep*. 2001;24(5):554-60.
3. Ryan CF, Love LL, Peat D, Fleetham JA, Lowe AA. Mandibular advancement oral appliance therapy for obstructive sleep apnoea: effect on awake calibre of the velopharynx. *Thorax*. 1999;54(11):972-7.
4. Giannasi LC, Mattos LC, Magini M, Costa MS, Oliveira CS, Oliveira LVF. The impact of the Adjustable PM Positioner appliance in the treatment of obstructive sleep apnoea. *Arch Med Sci*. 2008;4(3):336-41.
5. Almeida FR, Lowe AA, Sung JO, Tsuiki S, Otsuka R. Long-term sequellae of oral appliance therapy in obstructive sleep apnea patients: Part 1. Cephalometric analysis. *Am J Orthod Dentofacial Orthop*. 2006;129(2):195-204.
6. Giannasi LC, Almeida FR, Magini M, Costa MS, de Oliveira CS, de Oliveira JC, et al. Systematic assessment of the impact of oral appliance therapy on the temporomandibular joint during treatment for obstructive sleep apnea: long-term evaluation. *Sleep Breath*. 2009;13(4):375-81.
7. Goto S, Suzuki Y, Chiyojima N, Muta A, Ogino H, Tanaka Y, et al. Two cases of severe obstructive sleep apnea-hypopnea syndrome in which a mandibular advancing positioner was markedly effective. *Sleep Biol Rhythms*. 2003;1(2):127-9.
8. Parker JA, Kathawalla S, Ravenscraft S, Fox J, et al. A prospective study evaluation the effectiveness of a mandibular repositioning appliance (PM Positioner) for the treatment of moderate obstructive sleep apnea [abstract]. *Sleep*. 1999;22:S230.
9. Prinsell JR. Maxillomandibular Advancement (MMA) in a Site-Specific Treatment Approach for Obstructive Sleep Apnea: A Surgical Algorithm. *Sleep Breath*. 2000;4(4):147-54.
10. Li KK, Guilleminault C, Riley RW, Powell NB. Obstructive sleep apnea and maxillomandibular advancement: an assessment of airway changes using radiographic and nasopharyngoscopic examinations. *J Oral Maxillofac Surg*. 2002;60(5):526-30.; discussion 531.
11. Isono S. Contribution of obesity and craniofacial abnormalities to pharyngeal collapsibility in patients with obstructive sleep apnea. *Sleep Biol Rhythms*. 2004;2(1):17-21.
12. Downs WB. Variations in facial relationships; their significance in treatment and prognosis. *Am J Orthod*. 1948;34(10):812-40.
13. McNamara JA Jr. A method of cephalometric evaluation. *Am J Orthod*. 1984;86(6):449-69.
14. Mayer G, Meier-Ewert K. Cephalometric predictors for orthopaedic mandibular advancement in obstructive sleep apnoea. *Eur J Orthod*. 1995;17(1):35-43.
15. Otsuka R, Almeida FR, Lowe AA, Ryan F. A comparison of responders and nonresponders to oral appliance therapy for the treatment of obstructive sleep apnea. *Am J Orthod Dentofacial Orthop*. 2006;129(2):222-9.
16. Barthlen GM, Brown LK, Wiland MR, Sadeh JS, Patwari J, Zimmerman M. Comparison of three oral appliances for treatment of severe obstructive sleep apnea syndrome. *Sleep Med*. 2000;1(4):299-305.
17. Piskin B, Senturk F, Sevketbeyoglu H, Avsever H, Gunduz K, Kose M, et al. Efficacy of a modified mandibular advancement device for a totally edentulous patient with severe obstructive sleep apnea. *Sleep Breath*. 2010;14(1):81-5.
18. Ferguson KA, Ono T, Lowe AA, Keenan SP, Fleetham JA. A randomized crossover study of an oral appliance vs nasal-continuous positive airway pressure in the treatment of mild-moderate obstructive sleep apnea. *Chest*. 1996;109(5):1269-75. Comment in: *Chest*. 1996;109(5):1140-1.